

Anatomical Structures of the Limb of White-nest Swiftlet (*Aerodramus fuciphagus*) and White-headed Munia (*Lonchura maja*)

Zuki, A. B. Z.^{1*}, Abdul Ghani, M. M.¹, Khadim, K. K.¹, Intan-Shameha, A. R.¹ and Kamaruddin, M. I.²

¹Department of Veterinary Preclinical Sciences, Faculty of Veterinary Medicine, Universiti Putra Malaysia, 43400 Serdang, Selangor, Malaysia

²Division of Animal Technology Resources, Department of Veterinary Services, Ministry of Agriculture, Malaysia

ABSTRACT

The main aims of this study were to examine the anatomical structures of the pelvic limb of white-nest swiftlet and to find the reason why the birds are not able to walk, stand and perch while standing. The findings were compared with the white-headed munia which has almost similar body weight and appearance, and the above-mentioned abilities. Four left limbs from each type of the birds were examined macroscopically under the stereomicroscope, whereas the bones and muscles of both the species were measured and compared. The lengths of the femur and tibial bones of the two species were not significantly different, although the metatarsal bone and digits of the white-nest swiftlet were found to be shorter than those of the white-headed munia. In particular, the digits of the white-nest swiftlet were shorter and curvy as compared to the white-headed munia which has longer digits with straight and sharp claws. The limb muscles of white-nest swiftlets were smaller and thinner than the white-headed munia. Four muscle groups, namely, bicep femoris, semimembranous, semitendinosus and gastrocnemius, were also taken from each bird for histological examination. The muscle sections were stained with Haematoxylin and Eosin. Histologically, the white-nest swiftlets have relatively smaller muscle groups and muscle bundles as compared to the white-headed munia. Thus, the

limb is weak and unable to support its body weight. In conclusion, apart from the short metatarsal bone and digits, the small muscles of the limb could be the main reason for the inability of the white-nest swiftlets to use their limbs for walking, standing and perching while standing.

ARTICLE INFO

Article history:

Received: 7 February 2011

Accepted: 25 April 2011

E-mail addresses:

zuki@vet.upm.edu.my (Zuki, A. B. Z.), roki_adrian@yahoo.com (Abdul Ghani, M. M.), khalidkamd@yahoo.com (Khadim, K. K.), intan@vet.upm.edu.my (Intan-Shameha, A. R.), kamar@dvs.gov.my (Kamaruddin, M. I.)

* Corresponding author

Keywords: White-nest swiftlet, white-headed munia, bone, muscles

INTRODUCTION

White-nest swiftlets (*Aerodramus fuciphagus*) belong to the genus *Aerodramus* of small, dark, cave nesting birds in the Collocaliini tribe of the swift family *Apodidae*. Its members are confined to tropical and subtropical regions in Southern Asia, Oceania and North-eastern Australia. Many of its members were formerly classified in Collocalia, but were first placed in a separate genus by an American ornithologist, Harry Church, in 1906. Echolocation, DNA sequencing and parasitic lice have all been used to establish relationships between species (Chantler & Driessens, 2000). *Aerodramus* swiftlets are in many respects typical swifts, having narrow wings for fast flight, with a wide gap and small reduced beak surrounded by bristles for catching insects during flight. What distinguishes *Aerodramus fuciphagus* from other swifts, and indeed from almost all other birds, is their ability to use a simple but effective form of echolocation. This enables them to navigate within the breeding and roosting caves. The swiftlet's "sonar" consists of clicking sounds at the frequencies of 1,500 to 5,500 hertz, which are audible to the human ear and are emitted at the rate of about six times per second (Gausset, 2004). The nests of *Aerodramus fuciphagus* are constructed with saliva as a major component. In the two species, *Aerodramus fuciphagus* and the Black-nest Swiftlet or *Aerodramus maximus*, saliva is

the only material used, and the nests are collected for the famous Chinese delicacy known as "bird's nest soup". Nonetheless, over-collection has put pressure on the swiftlet populations (Jordan, 2004).

The white-headed munia (*Lonchura maja*) is a species of estrildid finch found in Indonesia, Malaysia, Singapore, Thailand and Vietnam. It is found in wetland habitat, especially in marshes and reeds (Crystal, 2010). Generally, they are similar to black-headed or chestnut munia, but have paler brown to whitish on the entire head and the throat is white. Young birds are brown on the upper parts with under parts and the face is buff. In Java and Bali, this is a fairly common and widespread bird in the area up to 1500 metres in height. The white-headed munia, like other munias, form large flocks during rice harvest but spread out in pairs during breeding season. The general behaviour of this species is similar to other munias (Crystal, 2010).

In this study, the pelvic limb muscles and bones of both species were grossly and histologically examined for the cross-sectional area of each muscle and muscle bundles of the thigh. The muscles taken for histology were only the prominent and important muscles for movement. To the authors' knowledge, the limb of white-nest swiftlets is not able to support their body weight, thus preventing the birds from standing and perching while standing, but allowing them to cling onto the vertical surface. However, the anatomical structure of the limb of swiftlets has not been fully documented. Thus, this study

was conducted with the objective to examine the differences in anatomical structures of the pelvic limb of the white-nest swiftlets (*Aerodramus fuciphagus*) and the white-headed munia (*Lonchura maja*).

MATERIALS AND METHODS

Birds and Sample Preparation

The study involved four adult birds from each white-nest swiftlet (*Aerodramus fuciphagus*) and white-headed munia (*Lonchura maja*). The white-nest swiftlets were taken from a farm in Tersat, Terengganu, in collaboration with the Department of Veterinary Services. The whole left pelvic limb from each bird was separated for dissecting. The white-headed munias were bought from a local bird shop in Sri Serdang. The birds were euthanized by cervical dislocation. The whole pelvic limbs of the left side of both birds were taken and fixed in the 10% formalin for two days before processed for histological examinations.

Macroscopic Examinations

The macroscopic examination of the pelvic limb was done under a stereomicroscope after two days of fixation in 10% buffered formalin. The muscles of the thigh and the leg of both the species of birds were dissected, measured and recorded. The dissected muscles of the limb were photographed and compared between the two species. The bones of the pelvic limb, which include the femur, tibia, metatarsus and digits, were also measured and recorded.

Histological Examinations

From each bird, the muscles of the left pelvic limb (*M. biceps femoris*, *M. semimembranosus*, *M. semitendinosus* and *M. gastrocnemius*) were taken for histological examinations. All the samples were washed with phosphate buffered normal saline pH 7.4, fixed in 10% neutral buffer formalin for 24 hr, and processed using standard histological procedures. Sections of 5µm thick were cut using a microtome (Leica 2045). The sections were mounted onto the glass slides and stained with the Haematoxylin and Eosin (Bancroft & Gamble, 2005). The sections were evaluated using a computerized image analyzer (Olympus image analysis, BX 51 TF) that was equipped with a camera CC12. The measurements of the muscle cross-sectional area and muscle bundle were performed by using a light microscope (Leica DM LB2, Germany) using a colour video camera. For each sample, six bundles were randomly and constantly selected in 100x magnifications, as well as measured at the middle of the bundle. The cross-sectional areas of the muscles and muscle bundles were measured under the same magnification.

Statistical Analysis

The means for the cross-sectional area of the muscles, cross-sectional area of the muscle bundles, the length of the femur, tibia and metatarsus, and the digits of the white-nest swiftlets and white-headed munia were analyzed using independent T test to compare the differences between the two

species. All the statistical analyses were performed using SPSS 12.0.

RESULTS

Macroscopic Examinations

Fig.1 shows the mean lengths of the pelvic limb bones of the white-nest swiftlets and white-headed munias. The results revealed that the length of femur ($11 \pm .1$ and $13 \pm .8$ for the white-nest swiftlets and white-headed munias, respectively) and tibia bones ($17 \pm .3$ and $20 \pm .6$ for the white-nest swiftlets and white-headed munias, respectively) were not significantly different ($P > 0.05$), although they were slightly shorter in white-nest swiftlets. However, the metatarsus ($9 \pm .4$ and $14 \pm .2$ for the white-nest swiftlet and white-headed munia, respectively) and digits ($4 \pm .5$ and $9 \pm .4$ for the white-nest swiftlet and white-headed

munia, respectively) were significantly shorter ($P < 0.05$) in the white-nest swiftlets than those of the white-headed munias (see Fig.2 and Fig.3). The digits of the white-nest swiftlets were short with curvy claws, while the digits of white-headed munia were longer, and the claws were rather straight and sharp (Fig.3).

All the pelvic limb muscles examined in this study were present in both the species. However, the size was very much different between the two species. Both the thigh and tibiotarsal muscles of the white-nest swiftlets were found to have smaller size as compared to the white-headed munias (see Fig.4 and Fig.5). Those muscles include the biceps femoris, semimembranosus, semitendinosus, quadriceps femoris, tensor faciae latae, gastrocnemius muscles, deep digital flexor muscle and long digital

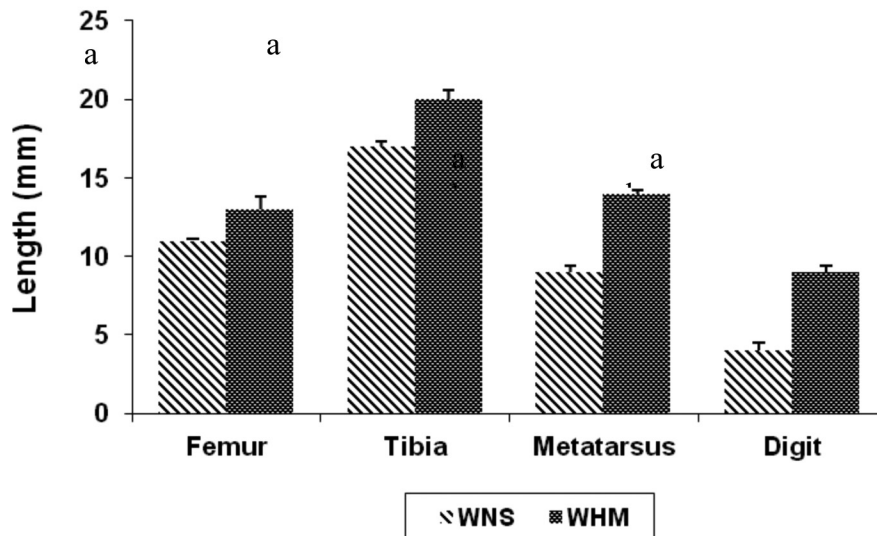


Fig.1: The white-nest swiftlets' (WNS) and white-headed munias' (WHM) length of the pelvic limb bones. Values are mean \pm SE. a, b different symbols indicate significant differences ($P < .05$)

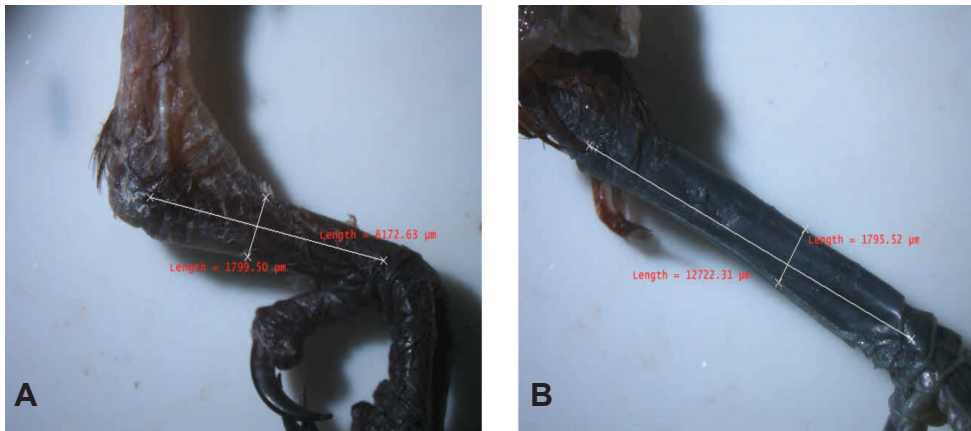


Fig.2: Photographs showing the metatarsal bone of (A) the white-nest swiftlet, and (B) white-headed munia. The metatarsal bone in A is much shorter than in B




Fig.3: Photographs of the digits of (A) the white-nest swiftlet, and (B) white-headed munia. The digits of the white-nest swiftlets are much shorter and curvy claw, which are suitable for clinging or hanging, while these are longer with straight claws for the white-headed munias for standing and perching purposes

extensor muscle. Nonetheless, the fibularis longus muscles of both species were found to be similar in size. The thigh muscles of the white-nest swiftlets were small and thin, which allow the femoral bone to be seen grossly, as shown in Fig.4.

Histological Examinations

Muscle Groups Area

The cross-sectional areas of the muscle groups of the white-nest swiftlets and white-headed munias are shown in Fig.6. The area of all the four selected muscles of the white-

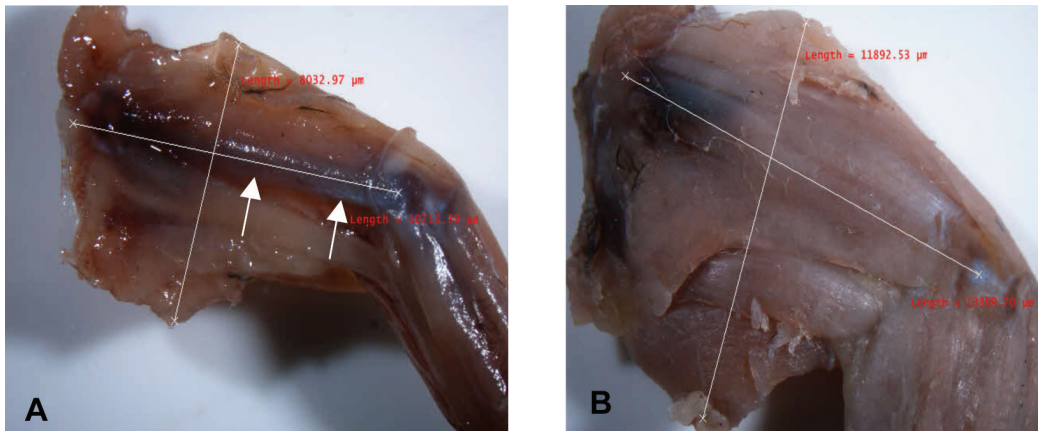


Fig.4: Photographs showing the thigh muscles of (A) the white-nest swiftlets and (B) white-headed munias. The thigh muscles in (A) are much smaller than in (B). Also note that the femur is grossly visible in (A) (arrows)

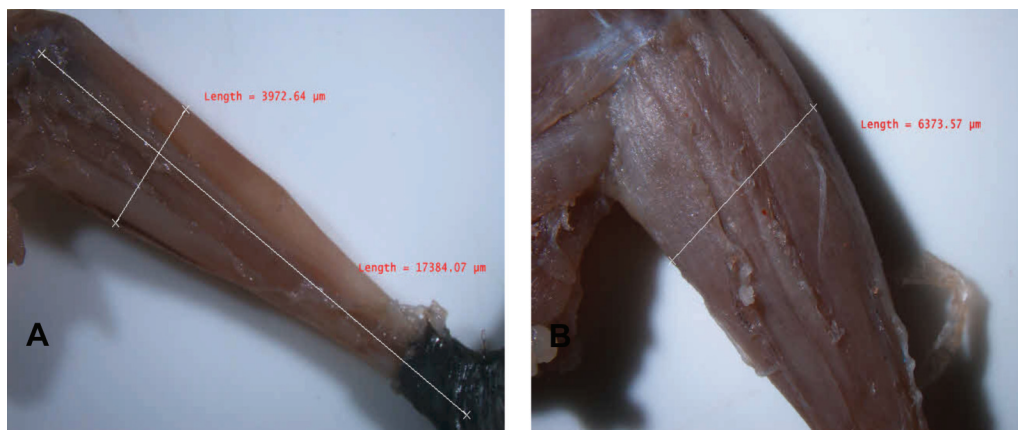


Fig.5: Photographs showing the muscles of the tibiotarsus of (A) the white-nest swiftlets and (B) white-headed munias. The tibiotarsal muscles in (A) are much smaller than in (B)

nest swiftlets were significantly smaller ($P < 0.05$) than the white-headed munia. In addition, the semitendinosus muscle of the white-nest swiftlets was particularly almost negligible.

Muscle Bundles Areas

The cross-sectional areas of the muscle bundles of the white-headed munias and

white-nest swiftlets are shown in Fig.7. The areas of the muscle bundles for the three muscle groups, namely the biceps femoris, gastrocnemius and semimembranosus muscles, were found to be significantly smaller ($P < 0.05$) in the white-nest swiftlets. In addition, the semimembranosus muscle bundles of the white-nest swiftlet were found to be smaller ($P < 0.05$) than the white-headed munias.

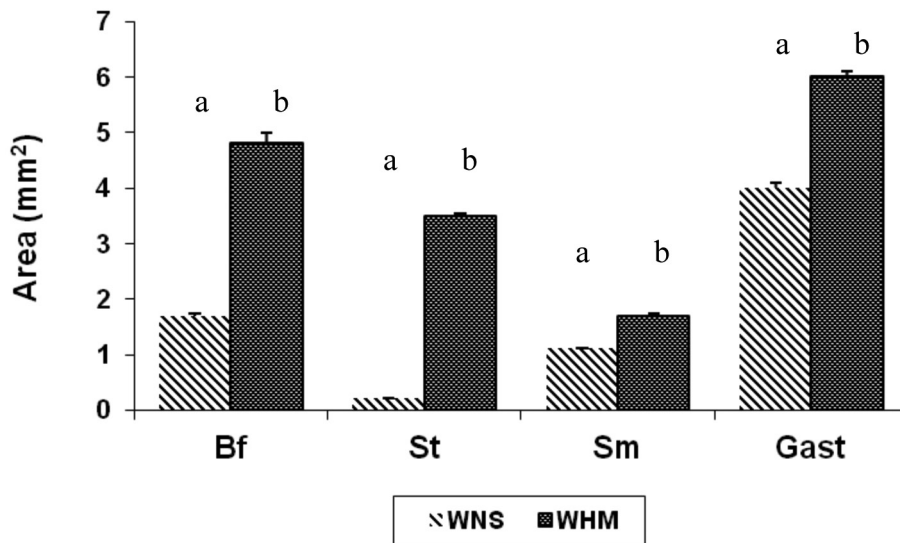


Fig.6: The cross-sectional area of the muscle groups of the white-headed munias and white-nest swiftlets; biceps femoris (Bf); semitendinosus(St); semimembranosus(Sm); gastrocnemius (Gast). The values are mean \pm SE a,b different symbols indicating significant differences ($P < .05$)

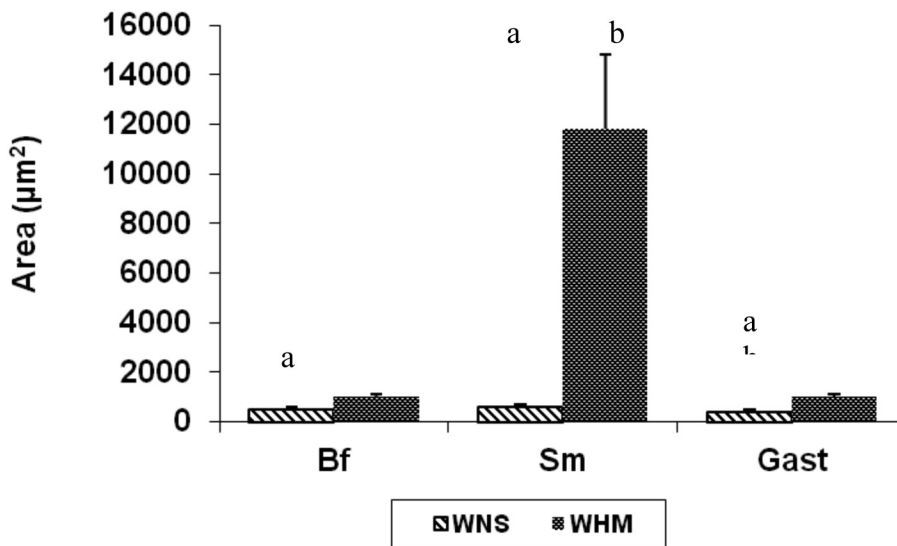


Fig.7: The cross-sectional area of the muscle bundles of the white-nest swiftlets (WNS) and white-headed munias (WHM). Biceps femoris (Bf); semimembranosus (Sm); gastrocnemius muscle (Gast). The values are means \pm SE. a,b different symbols indicating significant differences ($P < .05$)

DISCUSSION

Studies on the pelvic myology of the non-passerine birds are numerous. Among those which appear to be the most notable include the studies of the comparative functional morphology of the pelvic appendage in three genera of Cuculidae (Berger, 1952), the pelvic musculature in galliform birds (Hudson *et al.*, 1959), the anatomy of the locomotor apparatus of New World vultures (Fisher, 1946), the pelvic appendages of the Falconiformes (Hudson, 1937), the perforated flexor muscles in birds (Mitchell, 1894), the muscles of the avian (chiefly galliform) hip and thigh (Howell, 1938), and the peroneal muscles of various species (Mitchell, 1913).

The perching birds have the same requirements for the flexion and extension of the toes, a function that is performed by the muscles of the tibiotarsus and tarsometatarsus. The femur possesses muscles that are used in protracting and retracting the leg, as well as moving it in a lateral direction. These activities may be altered by variations in thigh musculature to compensate for the environmental requirements without affecting the success of perching. Therefore, the thigh is the region in which the greatest muscular variation may be expected.

In this study, the white-nest swiftlet (*Aerodramus fuciphagus*) from the family Apodidae and the white-headed munia (*Lonchura maja*) in the family Estrildidae were of the same body size and appearance; the difference between them is that the white-nest swiftlets lack the ability to walk

on the ground and perch while standing. The visible pelvic limb muscles, which are large enough and have the main effects on the movement and standing for both the birds, have been successfully identified and recognised. The results revealed that limb muscles observed in the white-nest swiftlets were also present in the white-headed munia. Thus, the white-nest swiftlets cannot be categorized as incapable birds.

The thigh and tibiotarsal muscles on the white-nest swiftlets, however, were smaller and thinner than the white-headed munias. Thus, this suggested that the pelvic limb muscles of the swiftlets were less developed as compared to the white-headed munias. The thigh muscles of the white-nest swiftlets were very small and thin that they caused the femur bone to be grossly visible. In contrast, the pelvic limb muscles of the white-headed munia were bigger and well developed. Thus, the reasons why the white-nest swiftlets are unable to walk or perch while standing can be explained by the small size of the limb muscles, in addition to the short metatarsus and digits.

According to Coues (1903), the high development of the shank muscles, which flex and extend the toes, has eliminated the need for a maximum development of the toe muscles. Furthermore, most of the toe muscles are for lateral movement of the toes, a function which is not beneficial to perch. Perching birds may be expected to have better developed toe muscles than terrestrial birds because of the need to maintain a constant flexed position (Coues, 1903). The results obtained for the white-headed munia

in this study agree with those by Coues (1903). However, this study revealed that in white-nest swiftlets, the thigh muscles were undeveloped and thus the ability to perch while standing is diminished.

The findings of this study also revealed that the metatarsus of the white-nest swiftlets was shorter than that of the white-headed munias. In addition, the digits of white-nest swiftlets were also short and curvy, which are suitable for clinging or hanging, whereas, the digits of white-headed munias were longer and straight with sharp claws that play an important role in standing and perching while standing.

Hence, the histological examinations of the cross-sectional muscle areas have revealed that the muscles area of four muscles in the white-nest swiftlets are smaller than those of the white-headed munias. In addition, the semitendinosus muscle area of the white-nest swiftlet was almost negligible, with very few muscle bundles present surrounded by the connective tissues. For the white-headed munias, on the contrary, the semitendinosus cross-section area was larger. This further suggested that the pelvic limb muscles of the white-headed munias were well developed as compared to the pelvic limb muscles of the white-nest swiftlets.

Muscle bundles are important to represent the whole muscle sizes. Thus, the measurement of the muscle bundles for each bird was taken. For the white-nest swiftlets, the sizes of the three muscle bundles (namely, biceps femoris, semimembranosus and gastrocnemius) were smaller than

those of the white-headed munias. The muscle bundles of the semimembranosus of the white-nest swiftlets were almost unrecognisable due to the presence of only a few muscle bundles which are surrounded mainly by the connective tissues. For the white-headed munias, on the contrary, the muscle bundles of the semimembranosus were much bigger and well-developed.

The results of this study agree with those of Hudson (1937) who noted that the eight muscles and the vinculum between *Mm. flexor perforans et perforatus digiti III* and *flexor perforatus digiti III* were missing in the order *Passeriformes*. In this study, all the eight muscles and the vinculum were missing in the white-headed munias (order *Passeriformes*) and the white-nest swiftlets (order *Apodiformes*). In addition, *Mm. adductor digiti IV* and *lumbricalis* were also absent. The muscles that were absent in the white-headed munias and the white-nest swiftlets were also absent in *Tyrannidae* (Tommy, 1971), Redwinged Blackbird (*Agelaius phoeniceus*) (Berger & George, 1966) and House Sparrow (*Passer domesticus*) (Berlin, 1963).

Hudson (1937) described the presence of the muscles that could be shown only by special staining techniques. Since the muscle structures are rudimentary and without tendons of insertion, their importance is questionable. Illustrating the presence of the muscles using the staining techniques, nonetheless, could produce misleading muscle formulae. The natural behaviours of the white-nest swiftlets (which are always on the air most of their

time, and using the wings rather than limbs) have weakened the muscles due to undeveloped pelvic limb muscles.

In conclusion, the lengths of the femur and tibial bones in both the species of birds were not significantly different, although the metatarsal bone of the white-nest swiftlets was shorter than that of the white-headed munias. The most significant findings in this study were the smaller and thinner muscles of the pelvic limb of the white-nest swiftlets as compared to the white-headed munias. Thus, the findings suggest that the limb muscles of the white-nest swiftlets are undeveloped, and this has caused them to become are weak and unable to support their own body weight.

REFERENCES

- Bancroft, J. D., & Gamble, M. (2002). *Theory and practice of histological techniques* (5th edition). New York:Churchill Livingstone.
- Berger, A. J. (1952). The comparative functional morphology of the pelvic appendage in three genera of Cuculidae. *The American Midland Naturalist*, 47, 513-605.
- Berger, A. J., & George, J. C. (1966). *Avian myology*. New York: Academic Press Inc.
- Berlin, O. G. W. (1963). A comparison of the hind limb musculature of the House Sparrow, *Passer domesticus* (Linnaeus), with that of the Blue Rock Pigeon, *Columba livia* (Gmelin). *Pavo*, 1(1), 48-51.
- Chantler, P., & Driessens, G. (2000). *Swifts: A Guide to the Swifts and Treeswifts of the World* (2nd edition). East Sussex: Pica Press.
- Coues, E. (1903). *Key to the North American Birds* (5th edn). Boston: The Page Company Publishers.
- Crystal (2010). *White-headed Munia*. Retrieved from <http://www.finchinfo.com>.
- Fisher, H. I. (1946). Adaptations and comparative anatomy of the locomotor apparatus of New World vultures. *American Midland Naturalist*, 35, 545-727.
- Gausset, Q. (2004). "Chronicle of a Foreseeable Tragedy: Birds' Nest Management in the Niah Caves (Sarawak)". *Human Ecology*, 32, 487-506.
- Howell, A. B. (1938). Muscles of the avian hip and thigh. *Auk*, 55, 71-81.
- Hudson, G. E. (1937). Studies on the muscles of the pelvic appendage in birds. *American Midland Naturalist*, 18, 1-108.
- Hudson, G. E., Lanzillotti, P. J., & Edwards, G. D. (1959). Muscles of the pelvic limb in galliform birds. *American Midland Naturalist*, 61, 1-67.
- Jordan, D. (2004). Globalisation and Bird's Nest Soup. *International Development Planning Review*, Volume 26. Liverpool University Press.
- Mitchell, P. C. (1894). On the perforated flexor muscles in some birds. *Proceedings of the Zoological Society of London*, 495-498.
- Mitchell, P. C. (1913). The peroneal muscles in birds. *Proceedings of the Zoological Society of London*, 1039-1072.
- Tommy, L. C. (1971). Myology of the pelvic appendage in the family *Tyrannidae*. A thesis in zoology, August 1971.